


# OCULAR Outlook

A QUARTERLY PUBLICATION FOR THE VETERINARY COMMUNITY FROM EYE CARE FOR ANIMALS

## OCULAR HEMORRHAGE: WHAT'S THE BLOODY CAUSE?

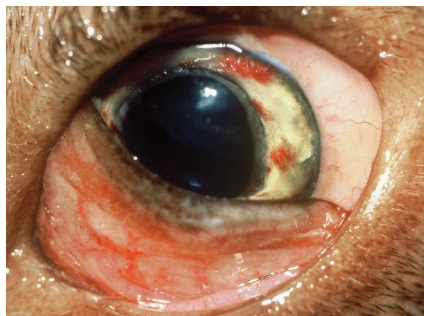

**B. Keith Collins,  
DVM, MS, DACVO**

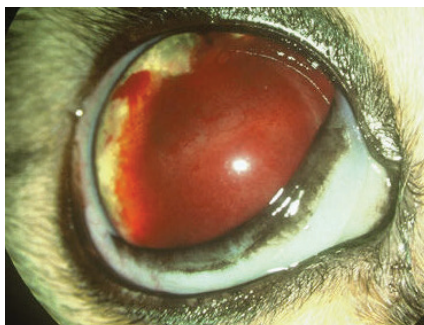Ocular hemorrhage is common and can affect the orbit, adnexa, or intraocular structures. Intraocular bleeding is most often encountered, and blood can be present in the anterior chamber (hyphema), the posterior segment (or vitreous), or the retina. Intralenticular bleeding is rarely observed unless associated with a congenital disorder. Hemorrhage can be minor and self limiting, or it can cause vision loss and indicate life-threatening disease (Figures 1 and 2). Possible causes include trauma, globe rupture secondary to ulceration, neoplasia, coagulopathy, systemic hypertension, infection, uveitis of any cause, and retinal detachment. It is helpful with differential diagnosis to consider various causes as single entities, but there is overlap. For example, ehrlichiosis could cause coagulopathy (due to

thrombocytopenia), uveitis, and retinal detachment, but the latter three conditions could occur alone in the absence of infection. A few specific causes and presentations are discussed.

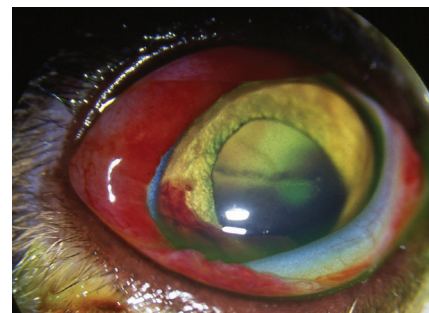Traumatic injuries to the globe or adnexa include lacerations, proptosis, crushing injuries (e.g., animal bite), blunt-force trauma (e.g., being hit by a ball), and penetrating corneal foreign bodies (Figure 3). Trauma is the obvious cause with lacerations, penetrating injuries, and most cases of proptosis, but caution is advised



**Figure 1: Iris hemorrhages in a dog with Rocky Mountain Spotted Fever.**



**Figure 2: Unilateral hyphema in a cat with systemic hypertension. The contralateral eye had serous retinal detachment but no hemorrhage.**



**Figure 3: Subconjunctival and intraocular hemorrhage in a cat following trauma.**

when assuming trauma in other instances. Consider the client who is adamant their pet "hit its head on the table" to cause blood in the eye. However, pre-existing disease might have contributed to the incident or exacerbated the result. A unilateral visual deficit (e.g., retinal detachment) for which the owner was unaware could have caused the pet to hit its eye on the affected side. Alternatively, undiagnosed thrombocytopenia could cause hemorrhage after an otherwise insignificant injury. Always look for a cause!

Rupture of a deep corneal ulcer (descemetocoele) can cause minor or

(CONTINUED ON PAGE 2)

### INSIDE THIS ISSUE

|                            |       |
|----------------------------|-------|
| Upcoming Events            | Pg. 5 |
| Article Spotlight          | Pg. 5 |
| Message from the President | Pg. 6 |

OCULAR Outlook

Editor: Keith Collins, DVM, MS, DACVO  
 Managing Editor: Debbie Brinkoetter

Eye Care for Animals welcomes your comments on the Ocular Outlook. Please e-mail your feedback to [dbrinkoetter@eyecareforanimals.com](mailto:dbrinkoetter@eyecareforanimals.com) or call Debbie at (480) 682-6911.

For electronic subscription please visit [www.eyecareforanimals.com](http://www.eyecareforanimals.com)

Eye Care for Animals  
 LOCATIONS

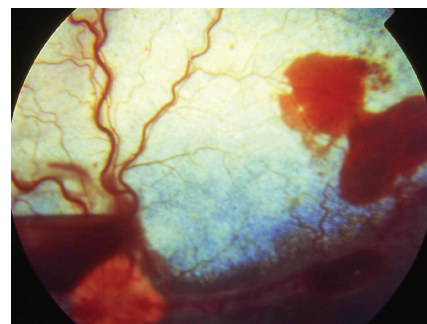
- Avondale, Arizona
- East Tucson, Arizona
- Gilbert, Arizona
- Phoenix, Arizona
- Scottsdale, Arizona
- South Scottsdale, Arizona
- Tucson, Arizona
- Chula Vista, California
- Corte Madera, California
- Culver City, California
- Palm Desert, California
- Pasadena, California
- San Diego, California
- San Juan Capistrano, California
- Santa Rosa, California
- Torrance, California
- Tustin, California
- Upland, California
- Woodland Hills, California
- Norwalk, Connecticut
- Chicago, Illinois
- St. Charles, Illinois
- Wheeling, Illinois
- Mission, Kansas
- Overland Park, Kansas
- Wichita, Kansas
- Annapolis, Maryland
- Frederick, Maryland
- Towson, Maryland
- Lee's Summit, Missouri
- Springfield, Missouri
- Las Vegas, Nevada
- Reno, Nevada
- Albuquerque, New Mexico
- Santa Fe, New Mexico
- Akron, Ohio
- Cleveland, Ohio
- Warwick, Rhode Island
- Austin, Texas
- El Paso, Texas
- Houston, Texas
- Round Rock, Texas
- Salt Lake City, Utah
- Sunset, Utah
- Leesburg, Virginia
- Pewaukee, Wisconsin

OCULAR HEMORRHAGE (CONTINUED FROM PAGE 1)

extensive bleeding. Surgical repair of the ulcer should be considered if anterior chamber bleeding is minimal and intraocular structures visualized. Complete hyphema associated with globe rupture carries a worse visual prognosis, and enucleation may be more appropriate for some of these patients.

Pets with ocular hemorrhage in the absence of known or visible trauma require additional evaluation. Accurate assessment requires complete ocular examination, physical examination, knowledge of breed predisposition for certain diseases, and selected tests. A complete blood count (CBC), platelet count, serum biochemical profile, blood pressure determination, coagulation profile, and serology for tick-borne or other diseases should be considered. Even in pets where hemorrhage is unilateral and physical examination unremarkable, minimum evaluation should include a platelet count and blood pressure determination. Ultrasound is helpful if hyphema precludes intraocular examination; however, the higher megahertz probes (10 MHz or greater) needed for ocular ultrasound may necessitate referral to an ophthalmologist. Enucleation should be considered for permanently blind or painful eyes where histopathology of the globe may facilitate diagnosis.

High blood pressure (or systemic hypertension) is a common cause of intraocular hemorrhage, and though symptoms are usually bilateral, they are not necessarily symmetric (Figure 2). The condition of hypertensive retinopathy refers to retinal changes that may include vascular tortuosity, hemorrhages, edema, degeneration, and detachment. Hypertensive retinopathy is the most common cause of retinal detachment and intraocular hemorrhage in cats greater than 10 years of age. Affected cats often have renal disease or hyperthyroidism. Chronic renal failure, diabetes mellitus, and Cushing's disease are common causes of hypertension in dogs. High-risk patients should



**Figure 4: Preretinal (boat keel) and intraretinal hemorrhages in a dog. The preretinal hemorrhage is adjacent to the optic disc.**

undergo periodic blood pressure determination and/or retinal examination for early diagnosis. Reduction in blood pressure and treatment of the primary disease can prevent progression of ocular changes, thereby preserving or even restoring vision. Blood pressure determination should be considered in all instances where the cause of bleeding is undetermined.

One definition of uveitis is breakdown of the blood-aqueous barrier, so it is not surprising that hyphema can occur with uveitis of any cause. This includes uveitis caused by leakage of lens protein from cataracts (i.e., lens-induced uveitis). Dogs with hypermature or rapidly resorbing cataracts are also at increased risk for retinal tears and detachment, and substantial hemorrhage can be associated with detachment. Thus, cataractous eyes can have hyphema due to lens-induced uveitis, retinal detachment, or both.

Retinal hemorrhages often develop in diabetic dogs with normal blood pressure and platelet function. The hemorrhages are a manifestation of diabetic retinopathy, but they are usually self-limiting and confined to the central or peripapillary retina. No specific treatment is required. Small intraretinal hemorrhages are occasionally encountered in non-diabetic dogs for which there is no discernible cause. The author has encountered idiopathic retinal hemorrhage most often in elderly Golden retrievers, and they are usually confined to the peripapillary

(CONTINUED ON PAGE 5)

# WELCOME!



## MARJORIE NEADERLAND DVM, DACVO

Dr. Marjorie Neaderland is a Norwalk, CT native. She received her Bachelor of Arts and Associates of Science from the University of Maine at Orono. After graduating, Dr. Neaderland worked as a research assistant at the Yale University School of Medicine in the Departments of Comparative Medicine and later, Therapeutic Radiology. She is the coauthor of several published papers involving hypoxic cell sensitization from that research project. Dr. Neaderland received her Doctorate of Veterinary Medicine from the University of California, Davis, in 1984. Following graduation from UC Davis, Dr. Neaderland completed a small animal medicine and surgery internship, and a three-year residency in comparative ophthalmology at Cornell University in New York. Her residency research project and publication involved equine corneal healing. She became a board certified veterinary ophthalmologist in 1990 and opened the Animal Eye Clinic in Norwalk. In June 2013, Dr. Neaderland joined Eye Care for Animals.

Dr. Neaderland is an avid equestrian and enjoys her equine patients. The Retinographics ERG was developed with Bill Eppler at her practice, bringing electroretinography into private ophthalmology practice. She is a supporter of the Pegasus Therapeutic Riding program, which provides handicapped children with physical therapy, companionship and confidence through horseback riding. She has been the veterinary ophthalmologist for the Guiding Eyes for the Blind in Patterson, NY since 1993, examining all dogs in their breeding program annually.



## DANIELLE PAGLIA DVM, DACVO

Dr. Danielle Paglia earned her Bachelor of Science degree in Animal Biology from the University of Florida. She obtained her Doctorate of Veterinary Medicine in 2001 from Mississippi State University where she was inducted into the Phi Zeta honor society. She then completed a rotating small animal medicine and surgery internship at Red Bank Veterinary Hospital. Subsequently, she attended the University of Wisconsin, Madison where she completed an ocular pathology fellowship. Following the completion of a three year comparative ophthalmology residency at the University of California, Davis, she worked in private practice in Rocklin, CA. She and her husband, a veterinarian and native Texan, have moved to Texas to be closer to family. She has joined ECFA in 2013 and practices at our Austin, TX location.

Dr. Paglia is the first at ECFA to do small animal **Mobile Ophthalmology**. By appointment, Dr. Paglia goes to predetermined Austin area veterinary practices to handle their ophthalmology needs and more easily accommodate the needs of their clients' pets.

---

## JOINING ECFA IN APRIL!

**Dennis Hacker, DVM, DACVO**

10324 San Pablo Avenue  
El Cerrito, CA 94530


# CONGRATULATIONS TO OUR NEWLY BOARDED DIPLOMATES!



**Melanie Church, DVM, DACVO,**  
Warwick, RI



**Dustin Dees, DVM, DACVO,**  
Austin, TX



**Kevin Fritz, DVM, DACVO,**  
San Diego, CA

# ARTICLE SPOTLIGHT

*Editor's note:* The spotlight is intended to provide practitioners with clinically relevant information from journals not available to most veterinarians. Old and new articles are included and are selected by the reviewer. This article was provided by Dr. Neal Wasserman



**Neal Wasserman,  
DVM, DACVO**

*Title:* Contralateral optic neuropathy and retinopathy associated with visual and afferent pupillomotor dysfunction following enucleation in six cats. *Vet Ophthalmol* 2013;1-12. DOI:10.1111/vop.12104

*Summary:* This study evaluates six cats in which visual and afferent pupillary dysfunction were noted after enucleation of the contralateral eye. All cats had mydriasis immediately after surgery. Four of six cats had absent menace, dazzle, and pupillary light reflexes; the remaining two had partial reflexes. Fundus, electroretinogram (ERG), and magnetic resonance imaging (MRI) findings were documented in some cats after surgery. Fundic changes noted between two and six weeks included peripapillary hyporeflexive and bullous lesions that eventually became flat and hyperpigmented. Optic nerve (ON) atrophy and retinal degeneration were noted as long-term sequelae. MRI findings three months or more after surgery revealed atrophy of the optic chiasm (OC).

*Comments:* The orbital space and sigmoid flexure of the ON are smaller in the cat than the dog. These differences reduce surgical

access to the posterior globe and allow for limited rostral mobility of the ON. Visual and pupillary light reflex deficits noted after enucleation indicated tractional damage to the OC and contralateral ON. Progressive fundic changes and MRI results support retrograde ON and retinal degeneration, and OC atrophy. The incidence of ON damage after feline enucleation is not clear, and the fact that all cats were not completely blind suggests the incidence may be greater than suspected. During surgery, the ON from the cats in this study were clamped, and the ON was ligated in four of the six cats where this information was available.

*Conclusion:* Much greater care is required when removing a cat's eye compared with a dog. Rostral traction of the globe and ligation of the ON should be avoided. Some ophthalmologists clamp the nerve prior to cutting it, but even this should probably be avoided. The consensus of most ophthalmologists is that bleeding can be controlled with direct tamponade alone.

## Spotlight on NEW LOCATIONS

**CLEVELAND, OHIO**  
5320 West 140th Street  
Brook Park, OH 44142

**SAN JUAN CAPISTRANO, CALIFORNIA**  
31896 Plaza Drive, Suite C-1  
San Juan Capistrano, CA 92675

**FREDERICK, MARYLAND**  
434 Prospect Blvd.  
Frederick, MD 21701

## Upcoming EVENTS

February 25, 2014 – Houston, TX  
MCVMA Mtg.

*Ophthalmology Dinner and CE*

March 26, 2014 – Chicago, IL  
*Wet Lab*

April 26, 2014 – Phoenix, AZ  
Arizona Specialty Center  
*"A Day With The Specialists" CE Event*

April 27, 2014 – Tustin, CA  
Advanced Veterinary Specialty Group  
*Multi Specialty Wet Lab*

## Special Thanks!

On behalf of the entire Eye Care for Animals family we thank Keith Collins, DVM, MS, DACVO for serving as Editor of Ocular Outlook these past two years. Congratulations on a job well done. We are extremely grateful for your service and commitment.

## OCULAR HEMORRHAGE (CONTINUED FROM PAGE 2)

retina. Ophthalmologists categorize retinal hemorrhages as preretinal, intraretinal, or subretinal, but such designations are not specific for any disease condition (Figure 4). Intraretinal hemorrhages can be subclassified as superficial or deep. Treatment of ocular hemorrhage is directed toward the underlying

cause. For non-ulcerated eyes in which hyphema is the primary finding, topical steroid and mydriatic treatment is appropriate as for other forms of uveitis. Additional specific treatment of anterior segment or posterior segment disease is determined by the results of additional tests. Depending on the cause and severity of disease,

additional treatment may include systemic antibiotics, corticosteroids, or hypotensive agents. Empiric doxycycline treatment should be considered in dogs where tick-borne disease is suspected and test results are pending. The visual prognosis will depend on the cause and severity of hemorrhage.

## HOW IS YOUR MEDICAL RECORD KEEPING?



**Karen Webster, MBA**  
President & CEO, Eye Care for Animals

At Eye Care for Animals various members of our doctor team serve on a Medical Review Committee. This Committee reviews any patient medical record at the request of a member of our doctor team and will compliment or make recommendations to the doctor on their medical record keeping. The Medical Review Committee also reviews challenging and unusual ophthalmic cases which are then shared with our doctor team. As a growing company with resident doctors in training, our Diplomates always stress the importance of having complete and thorough medical records. Because this documentation is so important, I looked to see what resources might be available to veterinarians and veterinary technicians who

are interested in enhancing their medical record keeping.

To refresh on medical record keeping protocols, there are several resources available. AAHA offers continuing education through a medical records management course at their school which can improve compliance and ensure consistency of care as well as reduce liability risks. A medical record keeping checklist can be found through DVM360 magazine which references the significant items that should be documented and detailed in the medical record. And, there is an on-line course on veterinary medical record keeping through [www.veterinaryrecordkeeping.com](http://www.veterinaryrecordkeeping.com). However, the latter on-line course

is only available for veterinarians and veterinary technicians when directed by the State Board. That course covers the key elements of proper veterinary medical record keeping as per the requirements of the 50 State Boards of Veterinary Medical Examiners, AVMA, and AAHA Level 3. Thorough and detailed documentation will help make your patient's medical record airtight and protect you should medical or standard of care questions arise by a client or the State Board.

A QUARTERLY PUBLICATION FOR THE VETERINARY COMMUNITY FROM EYE CARE FOR ANIMALS

# OCULAR *Outlook*

RESORTED  
STANDARD  
US POSTAGE  
PAID  
TUCSON, AZ  
PERMIT #414

