

OCULAR Outlook

A PUBLICATION FOR THE VETERINARY COMMUNITY FROM EYE CARE FOR ANIMALS

CANINE UVEITIS

A SCHNAUZER, A GOLDEN RETRIEVER & A HUSKY WALK INTO A BAR...

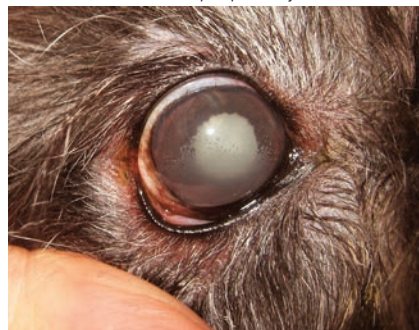by Douglas Esson BVSc, MRCVS, DVM, DACVO

The ocular uveal tract (from the Latin word uva or "grape") comprises the anterior iris and ciliary body and the posterior choroid (the rich vascular bed which supports retinal tissues). Inflammation of any or all of these tissues may broadly be termed "uveitis". Potential causes of uveitis include infectious, immune-mediated and neoplastic disease, however the exact etiology of ocular inflammation is often frustratingly elusive. The canine uveal tract typically exhibits an aggressive inflammatory response, frequently culminating in severe pain, glaucoma and/or blindness. These factors make for a clinical minefield. Here I present three relatively commonly encountered, yet often under- or misdiagnosed and ultimately unforgiving clinical conditions. These conditions, along with many others, have been detailed for the busy practitioner in my "Clinical Atlas of Canine and Feline Ophthalmic Disease."



describes severe, acute intraocular inflammation as a result of the sudden exposure to lens-associated proteins following lens capsule laceration or rupture.

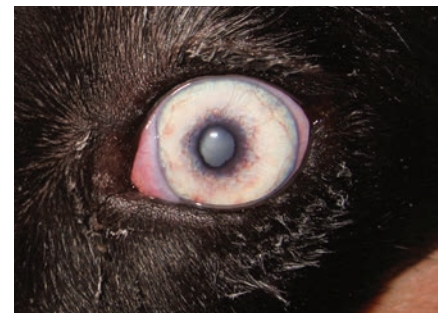Clinically, phacolytic uveitis may manifest as any combination of conjunctival/episcleral hyperemia, corneal edema, endothelial keratic precipitates, aqueous flare, iritis, iridal adhesions, pupillary miosis,



Lens induced uveitis exhibiting corneal endothelial keratic precipitates and posterior synechiae in a diabetic patient.

uveal cyst formation, ectropion uveae and/or decreased IOP. Any breed (commonly the Schnauzer) or cross-breed may be affected. The diagnosis of phacolytic uveitis is made based on clinical findings, in conjunction with the presence of a cataract.

Treatment of phacolytic uveitis should be undertaken in order to minimize the risk of secondary complications associated with chronic intraocular inflammation (notably retinal detachment and/or glaucoma). Treatment typically



Lens induced uveitis demonstrating ectropion uveae and iritis.

(CONTINUED ON PAGE 2)

Phacolytic (or "Lens Induced") Uveitis

Phacolytic (or "Lens Induced") Uveitis describes inflammation as a result of the leakage of lens-associated proteins across an intact lens capsule (especially in cases of rapidly forming cataracts such as those as associated with diabetes mellitus). *Note that even more severe "phacoclastic uveitis"

INSIDE THIS ISSUE

Locations	p. 2
New Diplomates & Residents.....	p. 3
ECFA is 35!.....	p. 4
Inaugural Best Practice Awards.....	p. 5
Baby Announcement.....	p. 6
Out and About.....	p. 7
Message from the President	p. 8

OCULAR Outlook

Editor: Christin Fahrer
DVM, MS, DACVO
Managing Editor: Debbie Brinkoetter

Eye Care for Animals welcomes your comments on Ocular Outlook. Please e-mail your feedback to dbrinkoetter@eyecareforanimals.com or call Debbie at (480) 682-6911.

For electronic subscription please visit www.EyeCareForAnimals.com

Eye Care for Animals LOCATIONS

Arizona

Avondale • East Tucson • Gilbert • Phoenix • Scottsdale • South Scottsdale • Tucson

California

Corte Madera • Culver City • El Cerrito • La Mesa • Palm Desert • Pasadena • San Diego • San Juan Capistrano • Santa Rosa • Torrance • Tustin • Upland • Woodland Hills

Connecticut

Norwalk

Florida

Tampa • Lakeland

Illinois

Chicago • St. Charles • Wheeling

Kansas

Mission • Overland Park • Wichita

Maryland

Annapolis (Bestgate Rd) • Annapolis (Defense Hwy) • Bel Air • Columbia • Frederick • Rockville • Towson

Missouri

Lee's Summit • Springfield

Nevada

Las Vegas • Reno

New Mexico

Albuquerque • Santa Fe

Ohio

Akron • Cleveland

Rhode Island

Warwick

Texas

Austin • El Paso • Houston • Round Rock • The Woodlands

Utah

Salt Lake City • Sunset

Virginia

Leesburg

Wisconsin

Pewaukee

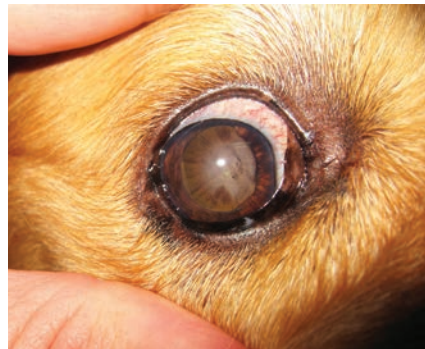(CONTINUED FROM PAGE 1)

encompasses topical (and where necessary systemic) (steroidal or non-steroidal) anti-inflammatory therapy. Where possible the long-term use of steroidal agents is avoided in the management of diabetic patients. Lens removal by phacoemulsification may be necessary in order to control severe uveitis and/or restore vision.

Golden Retriever Uveitis

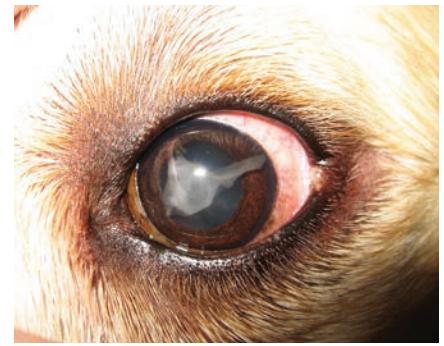A syndrome comprising slowly progressive intraocular changes, typically culminating in secondary glaucoma, is well recognized within the Golden Retriever breed. This syndrome has been variably described as "Pigmentary Uveitis", "Golden Retriever Uveitis" and "Pigmentary and Cystic Glaucoma of Golden Retrievers".

Findings may include any combination of conjunctival and/or episcleral hyperemia, corneal decompensation, thin-walled uveal cysts within the anterior or posterior chambers, proteinaceous exudation within the anterior chamber, anterior and/or posterior iridal adhesions, pigment dispersion



Golden Retriever Uveitis demonstrating radial pigment deposition across the anterior lens capsule.

within the anterior chamber and/or onto the anterior lens capsule, cataract formation, hyphema and/or secondary glaucoma. Uveal cysts may detach and move into the anterior chamber where they may rupture against corneal



Golden Retriever Uveitis demonstrating proteinaceous exudation within the anterior chamber.

endothelial and/or iridal surfaces or collapse and rupture within the iridocorneal angle. The hallmark of this syndrome has been described as the appearance of pigment on the anterior lens capsule, typically distributed in a radial orientation.

Initial symptoms are frequently noted in middle age and are usually bilateral, although not necessarily symmetrical. A genetic basis for this disease is suspected based on breed predilection as well as the absence of demonstrable infectious or neoplastic causes.

The diagnosis is made based on a combination of signalment and clinical findings. Treatment is generally empirical, frequently comprising topical and/or systemic anti-inflammatory (either steroidal or non-steroidal), immune-modulating (azathioprine or cyclosporine) as well as anti-glaucoma agents, however secondary glaucoma is frequently the end-point of this disease. Patients affected by advanced disease, represent high-risk candidates for either cataract or glaucoma surgery based on the frequency and severity of complications encountered.

Ultimately, a procedure of comfort (enucleation, cryosurgery, intrascleral prosthesis placement or chemical ciliary body ablation) may be necessary in order to address blind and/or painful eyes.

(CONTINUED ON PAGE 7)

CONGRATULATIONS TO: OUR NEWEST BOARDED DIPLOMATES

We congratulate Dr. Kim Hsu and Dr. Francesca Venturi, who each became a Diplomate of the American College of Veterinary Ophthalmologists in 2016. Dr. Hsu now becomes the sole doctor of our St. Charles practice and is the only veterinary retinal surgeon in Illinois. Dr. Venturi has moved from our Tustin, CA practice to full-time at our San Diego, CA practice.



Kimberly Hsu
DVM, MSc, DACVO



Francesca Venturi
DVM, DACVO

NEW RESIDENTS

We credit our world-class residency program for our success and welcomed Dr. Hannah Visser and Dr. Tara Czepiel to the program in July 2016. Dr. Visser will complete her three-year residency under the direction of Dr. Nicholas Millichamp in Houston, TX, and Dr. Tara Czepiel will complete her three-year residency under the direction of Dr. Neal Wasserman in Wheeling, IL.




Tara Czepiel, DVM
Ophthalmology Resident



Hannah Visser, DVM
Ophthalmology Resident

Clinical Atlas of Canine and Feline Ophthalmic Disease



A new book
written by
Douglas Esson

BVSc, MRCVS,
DVM, DACVO


Available via Wiley.com

NORWALK WELCOMES ANOTHER DOCTOR



Clinton Doering, Ph.D., DVM
Practice Limited to
Diseases of the Eye

In August 2016, Dr. Doering joined Dr. Neaderland full-time in our Norwalk, CT Practice.



The Eye Care for Animals App
Now Rolling Out for iOS and Android!



ECFA CELEBRATES 35TH BIRTHDAY/ANNIVERSARY FROM 3 PRACTICES TO 54..... AND GROWING!



Visionary Beginnings

Eye Care for Animals (ECFA) was founded back in 1981 by **Reuben E. Merideth, DVM, DACVO**, the same year he became a Diplomate of the American College of Veterinary Ophthalmologists (ACVO). When Dr. Merideth opened his first practice in Tucson, AZ, he immediately saw the need for veterinary ophthalmology services in other markets. Soon after, he opened practices in Mesa, AZ and Overland Park, KS, and started what would become the world's largest non-university residency training program.

An Expansion That Began On A Southwest Airlines Cocktail Napkin

As his successful practices were growing and other expansion opportunities were presenting themselves, Dr. Merideth realized he could no longer handle things on his own. It was now 1995, and time for a partner. The first person who came to mind was his former resident, **Paul Barrett, DVM, DACVO**.

Before long, Dr. Barrett had embraced a schedule much like that of Dr. Merideth, which consisted of airline travel throughout the week to meet the doctor needs of a growing veterinary ophthalmology business with multiple practices.

Southwest Airlines was their provider of choice and it's safe to say, the two became "regulars", adapting to routines that remain similar to this day. As they began implementing an administrative support services model, the talk of a long-term expansion plan came up, and it was at that moment Dr. Merideth pulled out a Southwest Airlines cocktail napkin - complete with a map of the United States and all 44 hubs at the time - and the planning began...



Dr. Reuben Merideth (left) and Dr. Paul Barrett (right) still fly Southwest Airlines weekly. 1998 was a record for Dr. Barrett with over 300 flights for ECFA. The doctors have made nearly 6,000 (combined) flights for ECFA on Southwest Airlines since becoming board certified veterinary ophthalmologists.

Over the years, the partnership grew to include 3 more owners/board members: **Julius Brinkis, DVM, DACVO, Randall Scagliotti, DVM, MS, DACVO and Nicole MacLaren, DVM, DACVO**. Today, ECFA is 54 practices strong... and still growing, with current representation in 16 states: AZ, CA, CT, FL, IL, KS, MD, MO, NM, NV, OH, RI, TX, UT, VA and WI. Without doubt, the

success of ECFA can be attributed to a world-class residency program that continues to help support the growth of the world's largest, veterinarian owned ophthalmology company, and the dedicated doctors, technicians and scores of support staff who are committed to the clients and patients they serve on a daily basis - 24 hours a day, 365 days a year.

(CONTINUED ON PAGE 6)

Introduction of Support Services Model



Randall Scagliotti, DVM, MS, DACVO introduced the concept of a centralized administrative support services model to Dr.

Merideth and Dr. Barrett in the late-nineties. The concept called for uniform, updated medical recordkeeping and corporate accounting practices, plus moving most administrative responsibilities out of the practice locations and concentrating them in one location. This move would enable clinical

practice staff to focus on patient care and customer service while keeping referring veterinarians informed about their patients.

The decision to give the model a try came to fruition when the company was changing incorporation in 2000, and it's in that process our expansion plan was actually born.

Today, the Service & Support Team is headquartered in Scottsdale, AZ and it is a model that has proved to be highly successfully for ECFA.

Thank you, Dr. Scagliotti!

INAUGURAL BEST PRACTICE AWARDS CEREMONY

Eye Care for Animals hosted the Inaugural Best Practice Awards Ceremony at the ECFA Annual Family Dinner during the American College of Veterinary Ophthalmologists (ACVO) conference at the end of October

2016. A Selection Committee determined the winners among 28 finalists - all who had received two practice level evaluations from Operations Manager Kristin Scillieri between September 1, 2012 through September 23, 2016.

It was an exciting evening for all those in attendance. A special THANK YOU was extended to EVERY ECFA practice - all are committed to the high performance standards measured in the evaluation process.

Congratulations 2016 Winners!



Eye Care for Animals - Wheeling, IL has A LOT to celebrate! Not only did they win the overall **BEST PRACTICE** award, but less than a week later the Chicago Cubs won the World Series!



Five **GOLD STANDARD PRACTICE** awards were presented to the Best Practice finalists:

- Akron, OH**
- Houston, TX**
- Gilbert, AZ**
- Pasadena, CA**
- Torrance, CA**



The **RISING STAR** award for most improved practice was awarded to **Avondale, AZ.**



Las Vegas, NV (runner-up)

Recognition

In August 2016, the National Association of Veterinary Technicians in America (NAVTA) recognized Veterinary Ophthalmology Technicians as the thirteenth veterinary technician specialty academy to the veterinary technology profession.

The Academy of Veterinary Ophthalmic Technicians (AVOT) board is hoping to open the official applications process in the Spring of 2017 with the first exam tentatively scheduled in 2018.

ECFA recognized this accomplishment with a congratulatory certificate at the group's annual conference in October. We support AVOT's mission to advocate ocular health while advancing the knowledge and practice standard of technicians in the field of ophthalmology.

BABY ANNOUNCEMENT - It's a Girl!!



Photo at left of the new baby girl from Cincinnati Zoo website. Photo on right, courtesy of Dr. Walter Burnham, shows Dr. Allison Hoffman with Andalus at the Sumatran Rhino Sanctuary.

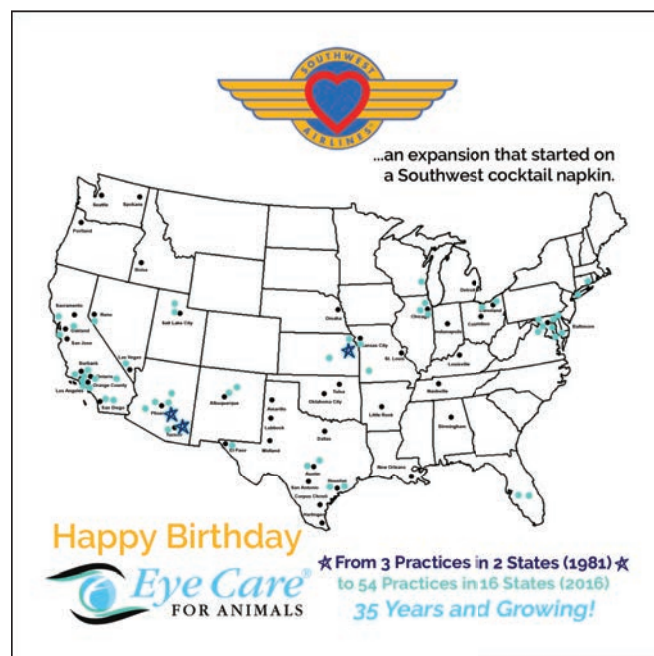A female Sumatran Rhino calf was born May 12, 2016 to mother Ratu and father Andalus, approximately 45 pounds and healthy, at the Sumatran Rhino Sanctuary in Indonesia's Way Kambas National Park. This birth holds particular significance to Eye Care for Animals due to Dr. Allison Hoffman's history with the baby's father, Andalus. Andalus is a Sumatran Rhino – the rarest of the five rhino species and one of the world's most endangered. Andalus was born in captivity at the

Cincinnati Zoo and grew up at the Los Angeles Zoo. He was transferred from the LA Zoo to the Sumatran Rhino Sanctuary in 2007. Dr. Hoffman surgically treated Andalus eye when he was at the LA Zoo, so when Andalus needed further eye surgery in 2014, the International Rhino Federation brought Dr. Hoffman in to do the job. This is the second rhino calf Andalus has sired and the second with Ratu. The first – a boy named Andatu – was born in 2012.

(CONTINUED FROM PAGE 4)

Keepsake Napkin

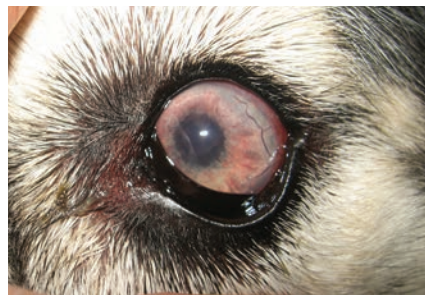The napkin pictured to the right is one-of-a-kind, prepared especially for the celebration of **Eye Care for Animals' 35th Birthday/ Anniversary**. The napkin reflects the 1995 Southwest Airlines logo and US map with the 44 cities marked that Southwest served at the time of ECFA's expansion plan meeting. The original 3 ECFA practices are marked with a star, plus the 54 green dots reflect ECFA's presence in the marketplace today.



(CONTINUED FROM PAGE 2)

Canine Uveodermatologic Syndrome (UDS)

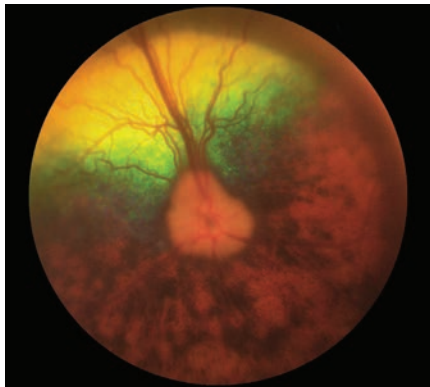
UDS represents an immune-mediated disease affecting melanocytic tissue, which likely has a hereditary etiology and which exhibits many similarities to Vogt-Koyanagi-Harada (VKH) disease in humans. Ocular symptoms associated with UDS may include inflammation marked by any combination of anterior



UDS exhibiting uveitis marked by episcleral hyperemia and iritis.

vitiligo (loss of pigment), poliosis (whitening of hair) and/or ulcerative dermatitis.

Typically these symptoms are relatively bilaterally symmetrical in appearance. Commonly affected breeds include the Akita, Siberian Husky, Samoyed, Chow Chow, German Shepherd and Shetland Sheepdog, however, other breeds may be affected. The diagnosis of UDS is made based on a combination of signalment & clinical findings. Where representative adnexal or dermal changes are present, a small incisional skin biopsy may support the diagnosis. Treatment usually comprises aggressive, long-term anti-inflammatory and/or immune-modulating therapy. Typically this involves the topical administration of corticosteroids and the systemic administration of corticosteroids with or without the adjunctive use of additional agents including cyclosporine and/or azathioprine.



UDS displaying chorioretinitis marked by multifocal depigmentation.

uveitis, chorioretinitis or panuveitis. Secondary changes may include any combination of cataract formation, retinal detachment, hyphema and/or glaucoma. Typically, both eyes are affected to a variable degree. Additional symptoms may include any combination of periocular, mucocutaneous oral and/or nasal



In addition to being our most recent doctor to publish a book, Dr. Esson has been featured in two recent episodes of *Sea Rescue*. In these episodes, he removed cataracts from a harbor seal and a sea lion that had been rescued by the team at Sea World California. Both procedures were successful and enabled the animals to be returned to the ocean. He is pictured above with one of his patients, Captain, the bottlenose dolphin at Sea World.

Out and About

Since August 2016, ECFA doctors and staff from coast to coast have taken part in over 40 events. From doctors providing continuing education presentations or wet labs at conferences and local VMA meetings, to sponsorship and participation of/at pet-related events in the community, and OFA clinics for breed clubs..... our doctors and their teams take pride in supporting the educational and philanthropic needs of their communities.

Join Our Team!

ECFA is seeking board certified or board eligible associates to join our great team of doctors. Flexible contract terms available and comprehensive compensation and benefits package including group health insurance, 401k, flexible schedule and continuing education.

- Freedom to practice medicine as you feel appropriate
- Cutting edge equipment and techniques
- Research opportunities

Please contact **Karen Webster** President/CEO

by Email:
kwebster@eyecareforanimals.com

or Phone:
480-682-6913

Positions Available Nationwide



OCULAR Outlook

A PUBLICATION FOR THE VETERINARY COMMUNITY FROM EYE CARE FOR ANIMALS

A "MUST-HAVE" FOR EVERY VETERINARY LIBRARY

A highlight of the past year has been seeing the "Clinical Atlas of Canine and Feline Ophthalmic Disease" by Douglas Esson, BVSc, MRCVS, DVM, DACVO in circulation around the world. As shared by the book's publisher, Wiley, Inc., it presents more than 600 high-quality color photographs depicting commonly encountered ocular conditions in dogs and cats. Multiple images are presented for each disease to show the varying presentations.

What I found particularly impressive is the book's organization. Most common conditions are presented first to make this an easy reference for busy veterinarians in clinical settings. The photography is exceptional and the summaries provide the relevant information necessary to diagnose and manage ophthalmic disease. This book is a must-have for every veterinarian's

clinical library as the most up-to-date resource and reference atlas available today.

Whereas Dr. Esson isn't the only doctor with Eye Care for Animals to publish a book, he is the latest, and a true reflection of what our board considers an example of our commitment to innovation. We value an environment that fosters innovative thinking and creative solutions to challenges. Maybe that's why it's no surprise that you can find any one of our 55 doctors featured in over 240 publications and abstracts to date.

Our Medical Quality Board and Research Committee, consisting of members of our ECFA doctor team, are committed to research and participating in clinical trials that help advance the ophthalmic care of animals. We encourage our doctors to be active beyond their daily clinical practice. Participation



by Karen Webster, MBA
President & CEO, Eye Care for Animals

in the teaching of future veterinary ophthalmologists by our doctors is what's helped us maintain a world-class residency program and bring more veterinary ophthalmologists into the field.

We applaud each of our doctors for his/her contributions to the advancement of veterinary ophthalmology and sincerely hope you enjoy and find useful the books, articles and abstracts they've shared for publication.